

4-2016

Bilateral Ovarian Dermoid Cysts' Treatment

Hilary Skalski
Grand Valley State University

Follow this and additional works at: <https://scholarworks.gvsu.edu/honorsprojects>



Part of the [Medicine and Health Sciences Commons](#)

ScholarWorks Citation

Skalski, Hilary, "Bilateral Ovarian Dermoid Cysts' Treatment" (2016). *Honors Projects*. 560.
<https://scholarworks.gvsu.edu/honorsprojects/560>

This Open Access is brought to you for free and open access by the Undergraduate Research and Creative Practice at ScholarWorks@GVSU. It has been accepted for inclusion in Honors Projects by an authorized administrator of ScholarWorks@GVSU. For more information, please contact scholarworks@gvsu.edu.

Grand Valley State University

Frederick Meijer Honors College

HNR 499-03 Honors Senior Project

Bilateral Ovarian Dermoid Cysts' Treatment

April 16th, 2016

Hilary Skalski

Table of Contents

Abstract.....	3
Introduction.....	4
Clinical Presentation.....	5
Imaging Procedures and Other Relevant Testing.....	6
Diagnostic Findings.....	9
Anatomy Involved.....	12
Histogenesis.....	13
Treatment.....	14
Prognosis.....	23
Conclusion.....	26
Appendix 1: Images.....	28
References.....	29

Abstract

Ovarian dermoid cysts are the most common neoplasm found in the ovary. They are also the most commonly removed ovarian neoplasm. Still, most reported cases of ovarian dermoid cysts are unilateral, so there is little research on bilateral ovarian dermoids. Nevertheless, bilateral treatment options should be explored, due to an increased likelihood of obtaining complications from a treatment or lack thereof. A meta-analysis on ovarian dermoid literature from 1991 to 2015 was performed to compile a treatment and prognosis for bilateral dermoids. The results found that a bilateral laparoscopic cystectomy was the optimal treatment method when treatment was desired. There was approximately an equal chance of complications from ovarian dermoids with or without surgery. There are several factors though that are put into consideration when making the decision. Ultimately, it is up to the patient and the doctor to decide on an individual case-by-case basis.

Introduction

Ovarian dermoid cysts are the most common neoplasm of the ovary (Stany & Hamilton, 2008). Also called mature cystic teratomas, these germ cell tumors account for about 20% of all benign ovarian tumors (Hoo et al., 2010). These cysts present most commonly as unilateral, though they can be found bilaterally in approximately 10-15% of cases (Hoo et al., 2010). Moreover, these dermoid cysts can occur at any age, unlike other germ cell neoplasms (Papadias et al., 2010). Still, they are increasingly prevalent in the reproductive years, where they account for 43-70% of all benign ovarian neoplasms (Sinha, 2010).

Due to the ovarian dermoid's prevalence, there have been numerous studies focused on the appropriate treatment for this pathology. Additionally, there have been many studies on ovarian dermoid cysts' treatment as a result of its prevalence in the female reproductive years. The importance of prevalence in the reproductive years is that the dermoids can cause infertility or other problems due to possible complications from the cysts removal or lack of removal. Due to these risks and complications, ovarian dermoid cysts are the most commonly removed ovarian neoplasm at 20-35% of all removed ovarian tumors (Outwater, 2001). The patient and doctor may choose to be proactive once the dermoid cyst is found and remove only the cyst before any possible complications arise with the ovary. This may be especially important if a woman has bilateral dermoid cysts, as both ovaries may need to be removed if complications develop. Even though bilateral dermoids are more likely to have complications, there is little research specifically on their treatment and outcomes (Hoo et al, 2010). Therefore, this paper attempts to

compile the treatment options, their factors and their outcomes to find the most appropriate treatment for bilateral ovarian dermoid cysts.

Clinical Presentation

Ovarian dermoid cysts are often asymptomatic (Stany & Hamilton, 2008). For instance, Tsikouras et al. (2008) found that 48% of the dermoid-removed patients were asymptomatic when their dermoids were discovered with a gynecological or ultrasound examination. Due to this lack of symptoms, ovarian dermoids are often discovered incidentally during a physical, imaging procedure, or a surgery of the pelvis or abdomen (Sinha, 2010). Moreover, Papadias et al. (2005) discovered 35% of ovarian dermoids on a routine pelvic examination. However, asymptomatic patients can possibly become symptomatic when the ovarian dermoid reaches a more considerable size (Tsikouras et al, 2008). Bilateral dermoid cysts have a greater chance of this occurring due to the combined volume effects (Hoo et al., 2010). When patients are symptomatic the most frequent symptom is lower abdominal pain. One study found that as many as 68% of patients had lower abdominal pain (Papadias et al, 2005). Other prevalent symptoms included: dysmenorrhea, abdominal pressure and bloating, and a palpated abdominal mass. Less common symptoms are back pain, bladder disturbances, and gastrointestinal complaints (Comerci et al, 1994).

Imaging Procedures and Other Relevant Tests

There are several tests to assist in the diagnosis of ovarian dermoids. This can involve any of the numerous radiology examinations including: Ultrasound, Computed Tomography (CT), and Magnetic Resonance Imaging (MRI). Additionally, blood tests for CA 19-9 and CA 125 can be performed.

Ultrasound. A transabdominal and transvaginal pelvic ultrasound is ordinarily the first diagnostic tool used in the diagnosis of ovarian dermoids (Patel et al., 1998). This is largely due to the higher expense and longer time needed with CT and MRI (Williams et al, 2011). Still, Tsikouras et al. (2008) states that transvaginal ultrasound is the optimal imaging technique to establish the nature of an ovarian dermoid cyst. Their study accurately diagnosed ovarian dermoids through ultrasound in 88% of cases, while the other 12% were diagnosed after an intraoperative histological frozen section. The most common appearance of ovarian dermoid cysts consists of highly reflective interfaces and posterior shadowing, which obscure the cyst's posterior wall. However, the sonographic appearance of ovarian dermoids varies, which can lead to the misdiagnosis of the cysts (Comerci et al., 1994). Ultrasound can greatly increase its accuracy in diagnosing the variable-appearing ovarian dermoids by the presence of more than one dermoid trait (Williams et al., 2011). Transvaginal ultrasound though may be inappropriate in some cases, including younger and non-sexually active females. Solely using transabdominal ultrasound and refraining from the use of transvaginal ultrasound may reduce the accuracy of the study. Controversially, transrectal imaging might be an applicable alternative approach to transvaginal imaging. However, some patients

may be opposed to the transrectal approach and therefore solely leaves the lower-quality transabdominal approach to ultrasound imaging (Takeda et al., 2005).

Computed Tomography. Computed Tomography (CT) can also be a good alternative for younger girls suspected with ovarian dermoids. In a study by Takeda et al. (2005), CT was used to diagnose ovarian dermoids in 86% of girls, ranging from age 10 to 15. Moreover, CT is exceptional in cases where the dermoid cyst is comprised of a fluid-fluid or fat-fluid level. It is the least common dermoid appearance at 3.4% of patients, though it is considered diagnostic of an ovarian dermoid when seen on CT (Caspi et al., 1996). Fat, along with bones and teeth, are also components seen well on CT as opposed to ultrasound (Stany & Hamilton, 2008). On the other hand, CT may be unnecessary if a diagnosis is clear on ultrasound. This is due to the increased expense and the increased amount of time necessary to complete CTs (Williams et al., 2011). In the study by Williams et al. (2011), CT is suggested only when patients have other features that suggest malignancy and is used to optimally stage the malignancy.

Magnetic Resonance Imaging. Magnetic Resonance Imaging (MRI) is another imaging procedure for the diagnosis of ovarian dermoids (*see Figures 1.1-1.3*). Like CT, MRI can be useful in the detection of masses containing fat (Comerci et al., 1994). Stany and Hamilton (2008) found that MRI identified dermoid cysts with a sensitivity of 100% and a specificity of 99%, due to the loss of T1-weighted signal when fat saturation was applied. Due to this accuracy, MRI is particularly helpful during pre-operative selection for surgery (Tsikouras et al., 2008). Similar to CT,

MRI is frequently needed solely for cases where further mass characterization is needed due to the exam's expense and lack of timeliness (Williams et al., 2011).

Laboratory Tests. In addition to radiology examinations, blood tests for CA 19-9 and CA 125 can be used in the diagnosis of ovarian dermoid cysts. CA 19-9 is currently used for the detection of pancreatic cancer, though a study by Coskun et al. (2008) showed that 100% of bilateral dermoid cases and 85% of unilateral dermoid cases displayed elevated levels of CA 19-9. The few other studies found similar results; still there is little research on the relationship between CA 19-9 and ovarian dermoid cysts. Additionally, CA 125 might be evaluated in ovarian dermoid cyst cases to rule out potential ovarian dermoid malignancy. A low-level of CA 125 would rule out malignant transformation of the benign dermoids. This tumor marker test is generally only useful in postmenopausal women since malignant ovarian tumors are more prevalent among older women. Moreover, the results are limited in accountability, as CA 125 has high false-positive and false-negative rates (Tsikouras et al., 2008).

Overall, ultrasound is typically the first test in the diagnosis of ovarian dermoids (Williams et al., 2011) and can have a 98% accuracy rate (Caspi et al., 1996). Still, CT and MRI may be used to confirm the diagnosis or rule out malignancy. Additionally, CT and MRI are especially useful in detecting the presence of fat within a mass, which can further firmly characterize an ovarian mass as a dermoid cyst (Patel et al., 1998 and Jung et al., 2002). MRI is also ideal for cases where ultrasound presentation is unusual. CT is moreover optimal for staging malignancy in cases where malignant ovarian dermoid cysts are suspected

(Williams et al., 2011). Finally, blood tests for tumor markers CA 19-9 and CA 125 have mixed results on their usefulness in ovarian dermoid diagnosis (Tsikouras et al., 2008 and Coskun et al., 2008).

Diagnostic Findings

Ovarian dermoid cysts have variable and multiple sonographic appearances, though there are several specific presentations or signs that help distinguish them. Some of these presentations include: a dermoid plug, the “tip of the iceberg” sign, a fat-fluid or fluid-fluid level, a cyst with pearl-gray appearance, and a dermoid mesh (Tongsong et al., 2008).

More specifically, the dermoid plug is a densely echogenic and homogenous mass arising from the wall in a cystic lesion. The echogenic projection is called the Rokitansky protuberance and contains soft tissue or fat mixed with hair. This dense echogenicity causes a shadow beyond the plug (Tongsong et al., 2008). The “tip of the iceberg” sign is also a presentation associated with dermoid cysts and it consists of a partially or diffuse echogenic mass (*see Figures 1.4 and 1.5*). This echogenic mass also usually demonstrates sound attenuation or shadowing due to the sebaceous material and hair within the cyst (Tongsong et al., 2008). Another typical dermoid appearance is the fat-fluid level, which occurs due to the anechoic sebum lying dependently below hyperechoic serous fluid (Owre & Pedersen, 1991). As mentioned earlier, the fat-fluid level is a rare dermoid presentation (Williams et al., 2011). The least common dermoid presentation is the dermoid mesh. This appearance consists of multiple thin echogenic lines and dots, which demonstrates

the hair within a dermoid cyst. This was found to be the highest individual or lone sonographic finding in dermoid cysts according to Patel et al. (1998) and had a 98% positive predictive value. In general though, the most common presentation seen was the shadowing echogenic Rokitansky protuberance (Williams et al., 2011).

As mentioned previously, ovarian dermoid cysts can be either unilateral or bilateral. Studies found bilateral dermoids in up to 28% of dermoid cases, with most studies obtaining an occurrence rate of 10-15% (Hoo et al., 2010). Where cases of unilateral dermoids are concerned, numerous studies found there to be a slight right-sided predominance with the highest being 72% (Coskun et al., 2008). Most right-sided predominances though were not statistically significant (Hoo et al., 2010 and Comerci et al., 1994).

The sizes of dermoid cysts also greatly vary. Studies show diverse mean diameters, though most lie within the range of 5 to 10 cm in diameter (Papadias et al., 2005). Papadias et al. (2005) found the largest dermoid diameter to be 16cm. Even with their wide range in size, ovarian dermoids are slow-growing masses with the average growth rate being 1.67-1.8mm/year (Hoo et al., 2010 and Stany & Hamilton, 2008).

Dermoid ovarian cysts can be both benign and malignant, with benign being the most common. Unfortunately, benign dermoid cysts are the most common benign adnexal mass mistaken for ovarian malignancy (Tongsong et al., 2008). Ultrasound's color Doppler can be a useful tool when diagnosing between benign ovarian dermoid cysts and ovarian malignancy. Malignant ovarian dermoid masses appear with high vascularization and usually lower resistance as compared to

benign dermoid cysts (Kurjak et al., 1997). Tongsong et al. (2008) found this to be an accurate statement as 100% of the benign ovarian dermoids showed little or no vascularization and a resistance index above 0.62, indicating that they were benign in nature.

Ovarian dermoid cysts are also associated with an increased risk of additional ovarian pathologies, specifically in certain types of ovarian cysts. Some of these cyst types are: functional cysts, endometriotic cysts, serous cystadenoma and mucinous cystadenoma. The most common of these four types is a functional cyst at 89% of dermoid cases with associated cyst pathology. Additionally, these cyst types are two times more likely to be on the contralateral ovary as compared to the ipsilateral ovary (Tsikouras et al., 2008).

Due to the dermoids' varying appearances, there are several structures and pathologies that can mimic ovarian dermoids. For example, bowel gas appears hyperechoic and casts a posterior acoustic shadow like a dermoid (Williams, et al., 2011), although bowel peristalses unlike a dermoid cyst (Tongsong et al 2008). Endometriomas can also look like dermoids if they have echogenic internal echoes in the wall from fibrosis or desiccated blood (Tongsong et al., 2008). Moreover, a tubo-ovarian abscess can mimic a dermoid because of its hyperechoic gas and fluid-fluid levels due to pus. On the other hand, tubo-ovarian abscesses typically have signs of sepsis and pain (Williams et al., 2011). Hemorrhagic cysts can also be confused with dermoids because of their hyperechoic echogenicity, though hemorrhagic cysts have increased through transmission (Outwater, 2001). Finally, pedunculated fibroids could mimic a dermoid due to their posterior shadowing and

the presence of calcification (Williams et al., 2011). Even with these numerous differentials, Tongsong et al. (2008) found a 94% sensitivity and 98% specificity for ovarian dermoids with sonographic imaging. Furthermore, Caspi et al. (1996) found a 98% accuracy rate for a dermoid cyst if that ovarian mass had two characteristic features of an ovarian dermoid cyst. Therefore, if there is any doubt of an ovarian mass being a dermoid versus a differential, they concluded that the presence of at least two dermoid sonographic characteristics is diagnostic.

Anatomy Involved

Ovarian dermoid cysts are composed of at least two of the three primitive germ cell layers from embryologic development (Pradhan & Thapa, 2014). These three layers include the endoderm, the mesoderm and the ectoderm. The endoderm is composed of mucinous or ciliated epithelium. The mesoderm is composed of muscle, fat, teeth, bone and cartilage. The ectoderm is composed of skin, hair and brain tissue (Pradhan & Thapa, 2014).

An ovarian dermoid is encompassed by a smooth milky-white glistening capsule, unless there is fat or hair underneath the capsule, which will then make it appear yellow or gray (Comerci et al., 1994). The majority of dermoids are unilocular and are filled with both solid and liquid components (Stany & Hamilton, 2008). The dermoid contents are normally liquid at body temperature, but may turn solid if cooled. The dermoid's contents are mostly made up of the liquid sebaceous material, but there may also be a solid Rokitansky protuberance that projects from the cyst's inner wall towards the center of the cyst. Hair, teeth, bone and adipose

tissue are among the many things contained in this nodule (Comerci et al., 1994 and Stany & Hamilton, 2008). The Rokitansky protuberance should be evaluated if removed, as it is a common site of cancer when there is malignant transformation (Comerci et al., 1994).

Histogenesis

The most common theory for the formation of dermoid cysts is the parthenogenic theory of origin. This theory states that mass formation is activated from an unfertilized egg (Stany & Hamilton, 2008). The parthenogenic theory is supported by studies that show ovarian dermoids containing a 46XX karyotype (Comerci et al., 1994). Cytogenic studies also support that ovarian dermoid cysts form from a sole germ cell after the first meiotic division. The locations of dermoid cysts in the body further support this theory, as the dermoids tend to migrate along the lines of primordial germ cells. These lines include the area from the yolk sac to the ovaries (Stany & Hamilton, 2008). Moreover, the parthenogenic theory of origin is supported by the prevalence of dermoid cysts during the reproductive years (Comerci et al., 1994).

Another more specific theory of origin is called the five mechanisms of origin mentioned by Sinha (2010). This concept states that there are five different times that dermoid cysts develop. They include: an error in meiosis 1, an error in meiosis 2, haploid ovum end reduplication, premiotic germ cell mitotic division, and fusion of two ovum.

Treatment

There are several treatment options for ovarian dermoid cysts. The three most common of these methods for ovarian dermoid cysts include: expectant management, laparotomy, and laparoscopy. Moreover with laparoscopy and laparotomy, a cystectomy, an oophorectomy, or a salpingo-oophorectomy can occur. The ovarian dermoid treatment option selected for each patient depends on numerous factors.

Expectant Management. One of the treatment options for women with dermoid cysts is expectant management. This involves known dermoid patients to receive follow-up ultrasounds to monitor the growth, appearance and any complications from the ovarian dermoid cysts. As mentioned previously, ovarian dermoid cysts are often asymptomatic and consequently, surgery might not be needed. In a study by Hoo et al. (2010), 70% of women who opted for expectant management, as compared to surgery, had no symptoms. The study also found a growth rate of the dermoid cysts averaging at 1.67mm/year and the largest successful dermoid cyst with expectant management measured at 34mm. The overall success rate for expectant management was 74.2%. On the other hand, the 25.8% of patients that underwent surgical removal partook mostly during the first two years of follow-up (Hoo et al., 2010). There were several reasons why the patients underwent surgery after expectant management. For example, 50% of patients had surgery due to patient request, 37.5% had surgery due to acquiring symptoms and 12.5% had the ovarian dermoids taken out during unrelated procedures (Hoo et al., 2010).

According to Hoo et al. (2010), there were some increased risks for expectant management failure, which made surgery necessary. One increased risk factor was found in younger women, when they were found to be 76% more likely to have surgery than women 10 years older than them. For example, several studies found that the mean age of women who had their ovarian dermoids removed was between ages 24 to 35 (Liberias et al., 2008 and Papadias, 2005). This population's frequency for removal might be merely due to a larger incidence of ovarian dermoid discovery at this age. Additionally though, it could be due to an increased concern for future fertility and less concern for surgical complications as a result of better health. The prevalence could also be due to an increased amount of time for symptoms to present further down the road. This increase in time will allow the dermoid cyst to grow in size, since it continuously growing (Hoo et al., 2010).

Another increase in risk was found in larger dermoid sizes. Patients who surgically removed their dermoid cysts had a mean dermoid size of 57mm, while patients who only underwent expectant management had a mean cyst size of 29mm. This could be due to the prevalence of obtaining symptoms in a larger dermoid cyst.

Additionally, a 12 times higher incidence of surgical removal was found in women whose parity was two or more. An explanation for this occurrence according to the study by Hoo et al. (2010) might be owing to the unwillingness to risk unexpected surgery with a significant family responsibility (Hoo et al., 2010).

Another increase in risk was found in women with bilateral dermoid cysts. Women with bilateral cysts were 18.4 times more likely to have surgical removal. One explanation is an increased risk in them becoming symptomatic as a result of

their combined volume effects. These patients can also be seen as having twice the risk of complications and therefore twice the potential risk of losing their ovaries to torsion. On the other hand, women had a reduced rate of surgical removal if they had a past history of ovarian cysts. These women were 90% less likely to have their dermoids removed (Hoo et al., 2010).

Overall, expectant management has a high success rate at 74.2% after 12.6 months. Expectant management is feasible for women who have an incidental finding of ovarian dermoid cysts and are therefore asymptomatic. On the other hand, expectant management might not be considered if the patient is younger, has larger dermoid cysts, has a parity of 2 or greater, or has bilateral cysts. Ultimately, it is up to the patient to decide and most women according to Hoo et al. (2010), most ovarian dermoid patients have a strong treatment preference.

Laparoscopy. Another treatment option for ovarian dermoid cysts is surgical removal. As stated earlier, 20-35% of all surgically removed ovarian tumors are dermoid cysts. In addition to the previously mentioned reasons, there are several reasons mentioned by Hoo et al (2010) to electively remove even asymptomatic dermoids. One of the reasons stated is the concern regarding the increasing difficulty of surgery due to the growth of the dermoid over time. This increase in size over time can cause an increase in the risk for torsion. Moreover it may be beneficial to remove the dermoids considering the risk of malignant transformation.

Laparoscopy has been stated as the surgical approach of choice for benign ovarian cysts (Tsikouras et al., 2008). Laparoscopy uses one to four small incisions,

with most commonly requiring three. These incisions are made with one incision in the umbilicus and two above or in the pubic hairline. Each of these incisions measures approximately a quarter inch in length (Somers, n.d.). With a laparoscopic approach, the surgeon inserts tools into the small incisions to manipulate the organs. They incise the ovary in an endopouch then rupture and aspirate the dermoid cysts, while trying to avoid spillage inside of the body cavity. The endobag can remove up to a 14 cm cyst through the small abdominal incision. After the cyst is removed, ovary requires hemostasis with cautery. This then allows the ovary to fold back on itself to close. If the dermoid was large, then sutures may be needed on the ovary and it will be wrapped in Interceed, which is a fabric material made of oxidized regenerated cellulose used to protect the healing ovaries from post-surgical adhesions. They then finish off by irrigating the peritoneal cavity with a saline solution (Walid & Heaton, 2010). Laparoscopic surgery's duration is found to last anywhere from 35 to 120 minutes, with the mean time taking about 60 minutes (Tsikouras et al, 2008 and Takeda, 2010).

Even though laparoscopic surgery uses a smaller field of view, it is still a reasonable treatment method for a dermoid cyst. The surgeon is adequately able to inspect the entire ovary for malignancy, perform adhesiolysis in case of adhesions, detect spilling of cyst contents, assess the size reduction and timing while aspirating, and perform extensive irrigation in case of cyst content spillage (Takeda, 2010). There are also several advantages and improved outcomes that make laparoscopic surgery the method of choice for dermoid cyst removal. Laparoscopic surgery might take a slight amount longer than laparotomy, though there are

several postoperative advantages to take into consideration. Some of these advantages include less chance of infection, less postoperative adhesions, reduced postoperative pain, decreased hospital stays and improved cosmetic results (Tsikouras et al., 2008).

On other hand, there are some negatives to using a laparoscopic approach for the removal of dermoid cysts. For example, the biggest factor of whether to use laparoscopy is the presence of a competent laparoscopic surgeon (Sinha, 2010). A laparoscopic approach is more difficult as compared to an open surgery due to the limited range of motion and the use of tools to manipulate the tissues (Somers, n.d.). Therefore, the surgeon should have significant experience with this method. Another limitation to using laparoscopy is that large cysts can cause difficulties when removed with this method. According to Papadimas et al. (2005), several dermoid cyst cases over 10cm caused problems when removed laproscopically. Therefore, if a dermoid cyst is taken out after allowing it grow awhile or if it is already large upon discovery, then a laparoscopic approach might not be practical. Finally, reoccurrence rates for laparoscopy are higher than for laparotomy (Sinha, 2010 and Stany & Hamilton, 2008). For example, Sinha's (2010) study found laparoscopic reoccurrence rates to be 7.6% as compared to laparotomy's 0%.

Laparotomy. When there are cases that limit or suggest against the use of laparoscopy for an ovarian dermoid cyst, then laparotomy is used. A laparotomy uses one midline incision below the umbilicus, but above the pubic bone. This incision ranges from 6-14 inches in length. This allows the doctor to directly view and manipulate within the operating field, as opposed to tools with laparoscopy

(Somers, n.d.). According to Takeda (2010), laparotomy is the standard procedure for the removal of large dermoid cysts. This is due to the tumor limiting the surgical field, the possibility of discovering malignant transformation, and the risk of dermoid contents spilling into the peritoneum, which can cause chemical peritonitis (Sinha, 2010). This occurs in only 1% of laparoscopic cases and can be reduced even more through a saline lavage after the spillage (Stany & Hamilton, 2008). Moreover, Tsikouras et al. (2008) suggests that laparotomy should be used only if malignant transformation is suspected or when intervention laproscopically is either inadvisable or not possible. Some of the common reasons against using laparotomy include: a poorer cosmetic appearance, greater post-operative pain, and a longer hospital stay and recovery time, as compared to a laparoscopic approach (Takeda 2010). Overall, a laparotomy used to be the standard treatment method for all dermoid cysts, however Tsikouras et al. (2008) states that: "Laparoscopic surgery has almost totally replaced laparotomy in the management of benign adnexal conditions".

Extent of Removal. There are several different amounts that can be excised in a laparoscopy or laparotomy dermoid removal, including a cystectomy, a partial or complete oophorectomy, or a salpingo-oophorectomy. There has been an important shift in the process for ovarian dermoid removal in the last 40 years, as doctors have increased the use of solely cystectomies for ovarian preservation and decreased use in contralateral biopsies (Comerci et al., 1994). Tsikouras et al. (2008) reasons that this conservative treatment may be due to the importance of preserving the ovaries for fertility purposes. Since most dermoid cysts affect the

younger population, treatment should take into consideration whether or not the patient desires future pregnancies. Still, Comerci et al. (1994) found the mean dermoid size for a cystectomy removal to be relatively small at 5.7 cm, therefore this option might not be a possibility for all dermoid cyst patients.

Another dermoid removal option is a partial or a complete oophorectomy. Cases of partial oophorectomies show indistinct cyst borders due to infection and they were mostly perimenopausal (Tsikouras et al., 2008). On the other hand, a complete oophorectomy is considered if the ovary is over 6cm in diameter. Comerci et al. (1994) found the complete oophorectomy mean dermoid diameter to be larger, at 8cm, as compared to the mean cystectomy's diameter, at 5.7 cm. Walid and Heaton (2010) suggest this due to a higher likelihood of spillage or rupture with a cystectomy if it is over 4cm. Comerci et al. (1994) further states that oophorectomies are an acceptable form of treatment if a cystectomy is impossible or if it is followed by uncontrolled hemorrhage. In general though it is important to warn the patient of this possibility ahead of time, especially if they desire future pregnancies. Another common reason for a complete oophorectomy is the lack of desire for future pregnancies (Stany & Hamilton, 2008). This can make removal a lot easier for the surgeon.

The final option in dermoid cyst removal is a salpingo-oophorectomy. This is a rare treatment form as most of the time it is not necessary to remove the fallopian tube. Some reasons that require the removal of the tube include the loss of functional ovarian tissue surrounding the cyst in a postmenopausal woman

(Tsikouras et al., 2008), a co-occurring ectopic pregnancy (Takeda, 2010), and an emergency surgery due to torsion (Takeda et al., 2005).

Special Cases. There are some patient populations that should receive special consideration. These include younger pediatric girls and pregnant patients. There are multiple cases of ovarian dermoids in pediatric patients as they are the most common ovarian tumor in patients under the age of 20. Pediatric girls display a challenge to physicians though as they have different anatomic and physiologic conditions, which need to be approached differently during surgery. For example, young girls' symptoms tend to be unspecific (Takeda et al., 2005). This leads to torsion being a lot more common in pediatric girls as compared to women and therefore emergency surgery occurs more often. This frequency is due to the longer oviduct, the higher position of the ovary, and the underdeveloped supporting tissue of the ovary found in a younger girl. Moreover in a young girl, the bladder sits higher and the aorta sits right under the thin umbilicus. This is important for the surgeon to know before they open their patient, since this knowledge could effectively change their surgical view and consequently their approach to operating. Finally, pediatric cases can be more problematic as a uterine manipulator cannot be used and an incisional hernia is more common. These disparities therefore require a surgeon who is experienced in these differences (Takeda et al., 2005). This is especially important since the goal for younger girls is to preserve as much ovarian tissue as possible for potential future fertility (Papadimas et al., 2005).

Pregnancy is also a special consideration when removing the ovarian dermoid cysts. The rate of dermoid cysts in pregnancy is 0.8 to 13% (Papadimas et al.

(2005). They are the most common ovarian tumor discovered during pregnancy (Tsikouras et al., 2008). Walid and Heaton (2010) suggest that an ovarian dermoid should be left alone in pregnant women if it is under 5cm in diameter. On the other hand, they state that if it is larger than 5 cm, then there is an increased risk for torsion, entrapment, rupture, peritonitis and adhesions. Tsikouras et al. (2008) found that the rate of complications for ovarian dermoid cysts was up to 22% during pregnancy. However, there are no commonly found complications from ovarian dermoid removal during pregnancy (Comerci et al., 1994). This might be why 21 to 40% of pregnant women with dermoids have them removed during pregnancy. Tsikouras et al. (2008) states that the best time for pregnant women to have their dermoids removed is the beginning of the second trimester. Walid & Heaton (2010) further suggested surgery during pregnancy if the dermoid cysts were bilateral to avoid any increased risk of complications.

In summary, surgical intervention is not necessary for ovarian dermoids, though a significant amount of people opt for surgical management. Laparoscopic treatment the ideal surgical method due to its increased cosmetic results, decreased infection rates, and decreased healing times (Tsikouras et al., 2008). Still, a laparotomy might be necessary due to an increased dermoid cyst size (Takeda, 2010). Moreover, a cystectomy is preferred for women who desire ovary conservation. This is commonly the most chosen method in the current field (Tsikouras et al., 2008). Other women might receive a complete oophorectomy due to a lack of interest for ovary conservation or due to the surgeon's concerns or complications to the ovary (Stany & Hamilton, 2008). Additionally, pediatric

patients and pregnant patients should obtain altered consideration due to their unique circumstance (Papadias et al., 2005). Finally, due to this compilation, bilateral ovarian dermoid cyst patients might lean toward surgery due to their increased risk for complications. More specifically, they might opt for bilateral cystectomies to help increase their chance for future fertility and a less drastic change in hormones.

Prognosis

There are several complications of ovarian dermoids that compel women to opt for elective surgical treatment. Some of the most common complications include torsion, rupture, hemolytic anemia, infection, and malignant degeneration (Stany & Hamilton, 2008).

Torsion is the most common complication of ovarian dermoid cysts occurring in 3-16% of cases (Sinha, 2010). It is also the most common cause of dermoid cyst morbidity (Stany & Hamilton, 2008). Torsion is the result of the ovary pedicle partially or completely twisting on its axis. This twisting can cause the vascular supply to be cut off, which can lead to congestion of the ovary and ischemia. The most common symptom of ovarian torsion is lower abdominal pain, but this can also be misdiagnosed with appendicitis if the pain is on the right side (Takeda et al., 2005). Research shows that larger ovarian dermoids are more likely to torse (Stany & Hamilton, 2008) with a mean diameter of 10.8cm in ovaries that torted compared to 6.3cm in ovaries that did not torse (Comerci et al., 1994). Even though torsion is not very prevalent, Takeda et al. (2005) found that two-thirds of torsion cases had

emergency surgery and had to remove the entire ovary. The study furthermore found that the maximum time they could save the ovary after the start of torsion was eight hours. Therefore, if there is any sign of necrotic change in the adnexa during ovarian torsion surgery, then the entire ovary needs to be resected. This is due to the irreversible change caused by the torsion with the presence of necrosis. There is also a possibility of thrombus with torsion, therefore untwisting the ovary lead to a possible, though unlikely, pulmonary embolism. On the other hand, if there is no sign of necrosis, then the surgeons will most likely try to keep the entire ovary. Surgeons do this by trying to untwist the ovary and see if blood flow returns to a normal color tone (Takeda et al., 2005).

Spontaneous rupture is another complication, which occurs in less than 1% of cases (Stany & Hamilton, 2008). According to Comerci et al. (1994), the dermoid's low rate of rupture is due to the cyst's thick capsule. Even though it is rare, rupture can be a serious complication, as it can result in hemorrhage or shock with acute chemical peritonitis (Stany & Hamilton, 2008). Still, the rate of infection is low at 1% of ovarian dermoid cases (Papadias et al., 2005).

Malignant transformation is another rare complication of ovarian dermoid cysts. This process occurs in around 1-3% of cases with a reoccurrence rate of up to 3-4% (Sinha, 2010). The most common component involved in malignant transformation is the squamous portion. This squamous cell carcinoma accounts for 80% of ovarian dermoid malignancies. These malignant changes tend to occur later in life at around the fifth to sixth decade of life (Papadias et al., 2005). Ovarian dermoid malignancy can have a similar appearance to the benign form with 31% of

malignant dermoid cysts having features of benign ovarian dermoids in the study by Tsikouras et al. (2008). Still, malignant dermoid cysts tend to be larger at 10-13cm (Papadias et al., 2005).

The prognosis is good for surgical removal of the dermoid cysts too. The amount of time spent in surgery is short at around a maximum of 2 hours (Sinha 2010). Moreover, the amount of recovery time in the hospital is short with most leaving the same day, but with a maximum of 2 days (Liberis et al., 2008). Furthermore, the reoccurrence rates are low for surgical removal (Sinha, 2010). In addition, fertility rates remain unaffected by surgery. For example, a study by Tsikouras et al. (2008), found that of the patients who desired pregnancy, 86% of them were able to conceive naturally. Of these cases, all but one went to full term and none of the cases had any fetal abnormalities. On the other hand, women with bilateral dermoid cysts have a greater chance of developing germ cell neoplasms in the future (Sinha, 2010).

Even though there is a generally favorable prognosis with surgery, there are many complications that can occur with the removal of ovarian dermoids cysts. Some complications include injuries to the epigastric arteries, adhesions, spillage and subsequential peritonitis (Tsikouras et al., 2008). Adhesions can be inevitable due to larger incisions needed for larger cysts, though anti-adhesion agents can reduce their frequency. Moreover, spillage can occur from the ruptured dermoid cysts and can then cause peritonitis. This is relatively common occurrence with laparoscopy ranging anywhere from 18 to 42% of cases having some form of spillage (Stany & Hamilton, 2008). Even though spillage is a common occurrence,

there are few cases of peritonitis and postoperative complications due to thorough irrigation (Tsikouras et al., 2008). Furthermore, most studies did not contain any cases with complications (Sinha, 2010; Liberis et al., 2008; Takeda, 2010; Takeda, 2005).

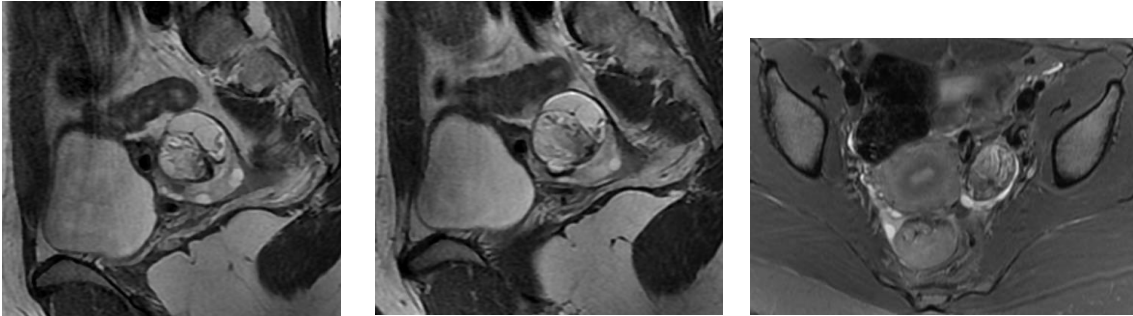
In summary, the prognosis for ovarian dermoids is good, even if they are not surgically treated. The risk for complications, like rupture and malignant transformation, even without surgery is low. Still, the complications can be can result in the loss of the ovary, like torsion, or death, with peritonitis. Prognosis for surgical removal of the dermoids is favorable also, with most cases occurring without any complications. The most frequent complication is spillage, but this can easily be resolved with irrigation of the abdominal cavity before closure. In taking into consideration all of the compiled data, prognosis for bilateral ovarian dermoid cysts is good, even without the removal of the cysts. Still, it might help patients feel more secure in their chances at fertility if they are removed prematurely to any possible complications.

Conclusion

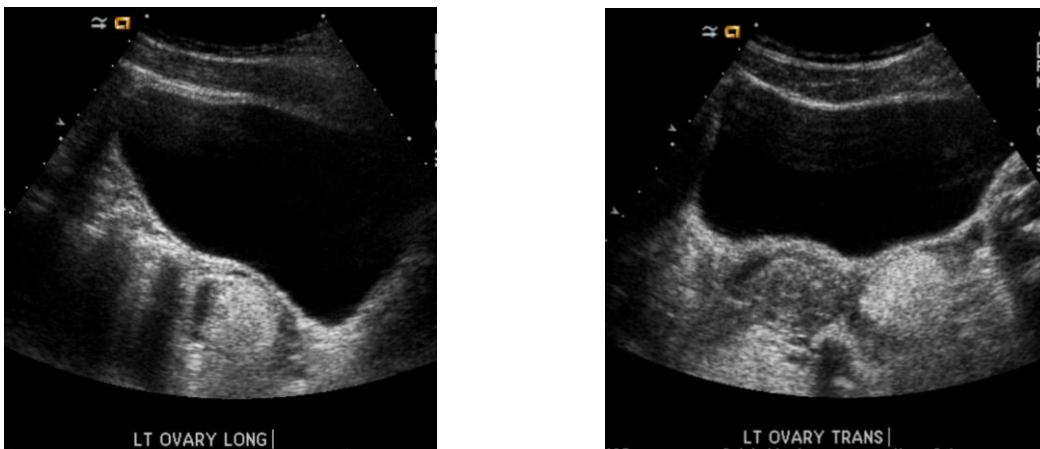
Dermoid cysts are benign germ cell tumors. They are the most common neoplasm found in the ovary. Ovarian dermoid cysts are most prevalent during the reproductive age and are mostly unilateral. Due to their prevalence and their predominance in reproductive years, there have been many studies done investigating ovarian dermoids. With that being said, there is a significant amount of research on the treatment of ovarian dermoids, though there is little research on

bilateral cases. Still, there is significance in the investigation on bilateral dermoids due to their increased chance of complications like infertility and loss of the ovary. A compilation of research from multiple studies over the course of 25 years indicate that it should be the individual patient and doctor's choice whether or not to operate. This is based on preferences and specific case factors. There is a small chance of complications if not treated, though the risk of complications from surgery is about the same. Bilateral ovarian dermoid cysts do increase the risk of complications and factors such as dermoid size, patient age, desire for infertility, pregnancy, and chances of malignancy can highly affect the likelihood of complications from a treatment decision.

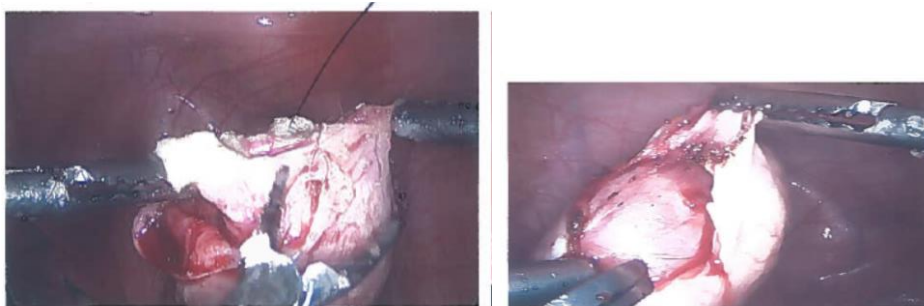
Appendix 1: Images



Figures 1.1- 1.3. MRI images of ovarian dermoid cysts.



Figures 1.4 and 1.5. Ultrasound images of an ovarian dermoid demonstrating an iceberg appearance.



Figures 1.6 and 1.7 Images obtained during a laparoscopic cystectomy surgery to remove bilateral ovarian dermoids.

Works Cited

- Caspi, B., Appelman, Z., Rabinerson, D., Elchalal, U., Zalel, Y., Katz, Z. (1996). Pathognomonic echo patterns of benign cystic teratomas of the ovary: classification, incidence and accuracy rate of sonographic diagnosis. *Ultrasound of Obstetrics and Gynecology*. 7. p. 275-279.
- Comerci, J.T., Licciardi, F., Bergh, P.A., Gregori, C., Breen, J.L. (1994). Mature cystic teratoma: a clinicopathologic evaluation of 517 cases and review of the literature. *Obstetrics and gynecology*. 84(1). p. 22-28.
- Coskun, A.; Kiran, G.; Ozdemir, O. (2008). CA 19-9 can be a useful tumor marker in ovarian dermoid cysts. *Clinical and experimental obstetrics and gynecology*. 35(2). p. 137-139.
- Hoo, W.L., Yazbek, J., Holland, T., Mavrellos, D., Tong, E.N.C., Jurkovic, D. (2010). Expectant management of ultrasonically diagnosed ovarian dermoid cysts: is it the possible to predict the outcome? *Ultrasound of Obstetrics and Gynecology*. 36. p. 235-240.
- Jung, S.E., Lee, J.M., Rha, S.E., Byun, J.Y., Jung, J.I., Hahn, S.T. (2002). CT and MR imaging of ovarian tumors with emphasis on differential diagnosis. *RadioGraphics: RSNA education exhibit*. p. 1305-1325.
- Kurjak, A., Kupesic, S., Babic, M.M., Goldenberg, M., Illijas, M., Kosuta, D. (1997). Preoperative evaluation of cystic teratoma: What does color Doppler add? *Journal of Clinical Ultrasound*. 25(6). p. 309-316.
- Leberis, V.; Tsikouras, P.; Sivridis, E.; Dadidou, M.; Koutlaki, N.; Galazios, G. (2008). Irregular dental structures in a benign ovarian cystic teratoma (dermoid cyst): case report. *Clinical and experimental obstetrics and gynecology*. 35(2) p. 151-152.
- Outwater, E.K.; Siegelman, E.S.; and Hunt, J.L. (2001). Ovarian teratomas: tumor types and imaging characteristics. *Radiographics*. (21)2. p.475-490.
- Owre, A. and Pedersen, J.F. (1991). Characteristic fat-fluid level at ultrasonography of ovarian dermoid cyst. *Acta Radiologica*. 32 (4). p. 317-318.
- Papadias, K.; Kairi-Vassilatou, E.; Kontogiani-Katsaros, K.; Argeitis, J.; Kondis-Pafotos, A.; Greetsas, G. (2005). Teratomas of the ovary: a clinic-pathological evaluation of 87 patients from one institution during a 10-year period. *European journal of gynaecological oncology*. 26(4) p. 446-448.
- Patel, M.D., Feldstein, V.A., Lipson, S.D., Chen, D.C., Filly, R.A. (1998). Cystic teratomas of the ovary: Diagnostic value of sonography. *American Journal of Roentgenology*. 171. p. 1061-1065.
- Pradhan, P. and Thapa, M. (2014). Dermoid cyst and its bizarre presentation. *Journal of Nepal Medical Association*. 52(194). p. 822-829.
- Rangrass, R. (2015). Hilary Skalski's laparoscopic cystectomy surgery images. Obtained on 8/7/15.
- Sheth, S., Fishman, E.K., Buck, J.L., Hamper, U.M., Sanders, R.C. (1988). The variable sonographic appearances of ovarian teratomas: Correlation with CT. *American Journal of Roentgenology*. 151(2). p. 331-334.

- Sinha, R.; Sethi, S.; Mahajan, C., Bindra, V. (2010). Multiple and Bilateral Dermoids: A case report. *The Journal of Minimally Invasive Gynecology*. 17(2). p. 235-238.
- Somers, J. (n.d.). Laparoscopy vs. Laparotomy for Surgical Procedures. Retrieved from: <http://www.joannsomersmd.com/health/surgeries.php>.
- Stany, M.P. and Hamilton, C.A. (2008). Benign disorders of the ovary. *Obstetrics and gynecology clinics of North America*. (35)2. p.271 - 284.
- Takeda, A. (2010). Minimally invasive management of large ovarian cysts by gasless laparoscopic-assisted surgery. *Ovarian cysts: Symptoms, causes and treatment*. p. 145-148.
- Takeda, A., Manabe, S., Hosono, S., Nakamura, H. (2005). Laparoscopic surgery in 12 cases of adnexal disease occurring in girls aged 15 years or younger. *The Journal of minimally invasive gynecology*. 12. p. 234-240.
- Tongsong, T., Luwan, S., Phadungkiatwattana, P., Neeyalavira, V., Wanapiak, C., Khunamornpong, S., Sukpan, K. (2008). Pattern recognition using transabdominal ultrasound to diagnose ovarian mature cystic teratoma. *International Journal of Gynecology and Obstetrics*. 103. p. 99-104.
- Tsikouras, P., Liberis, V., Galazios, G., Savidis, A., Teichmann, A.T., Vogiatzaki, T., Zervoudis, S., Maroulis, G. (2008). Laparoscopic treatment of ovarian dermoid cysts. *Clinical and Experimental Obstetrics & Gynecology*. 35(2). p.124-129.
- Walid, M.S. and Heaton, R.L. (2010). Laparoscopic treatment of low-risk cystic masses of the ovary. *Ovarian Cysts: Symptoms, causes and treatment*. p. 159-168.
- Williams, P. L., Dubbins, D. E., & Defriend, D. E. (2011). Ultrasound in the diagnosis of ovarian dermoid cysts: a pictorial review of the characteristic sonographic signs. *Ultrasound*, 19(2), 85-90.